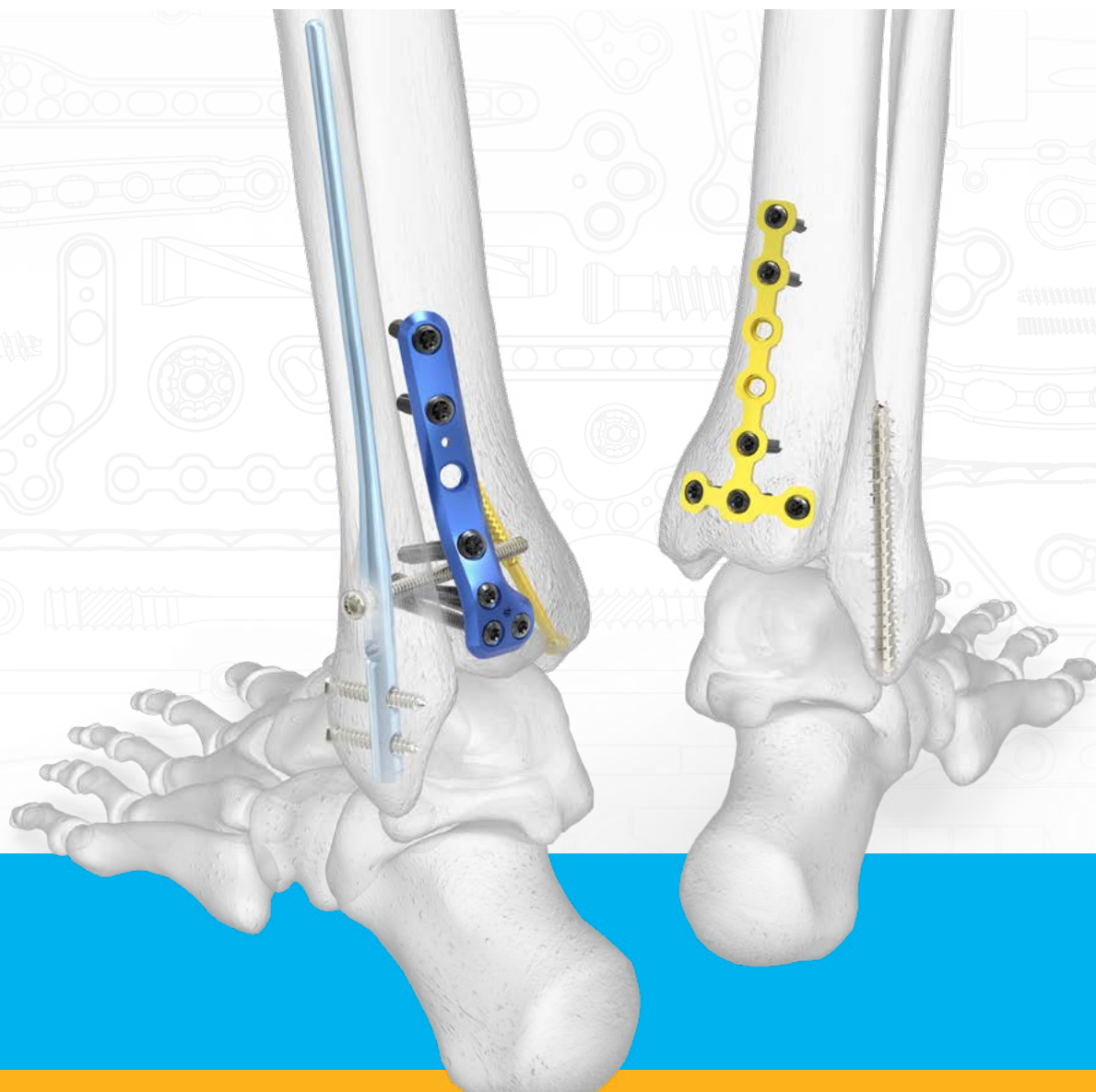
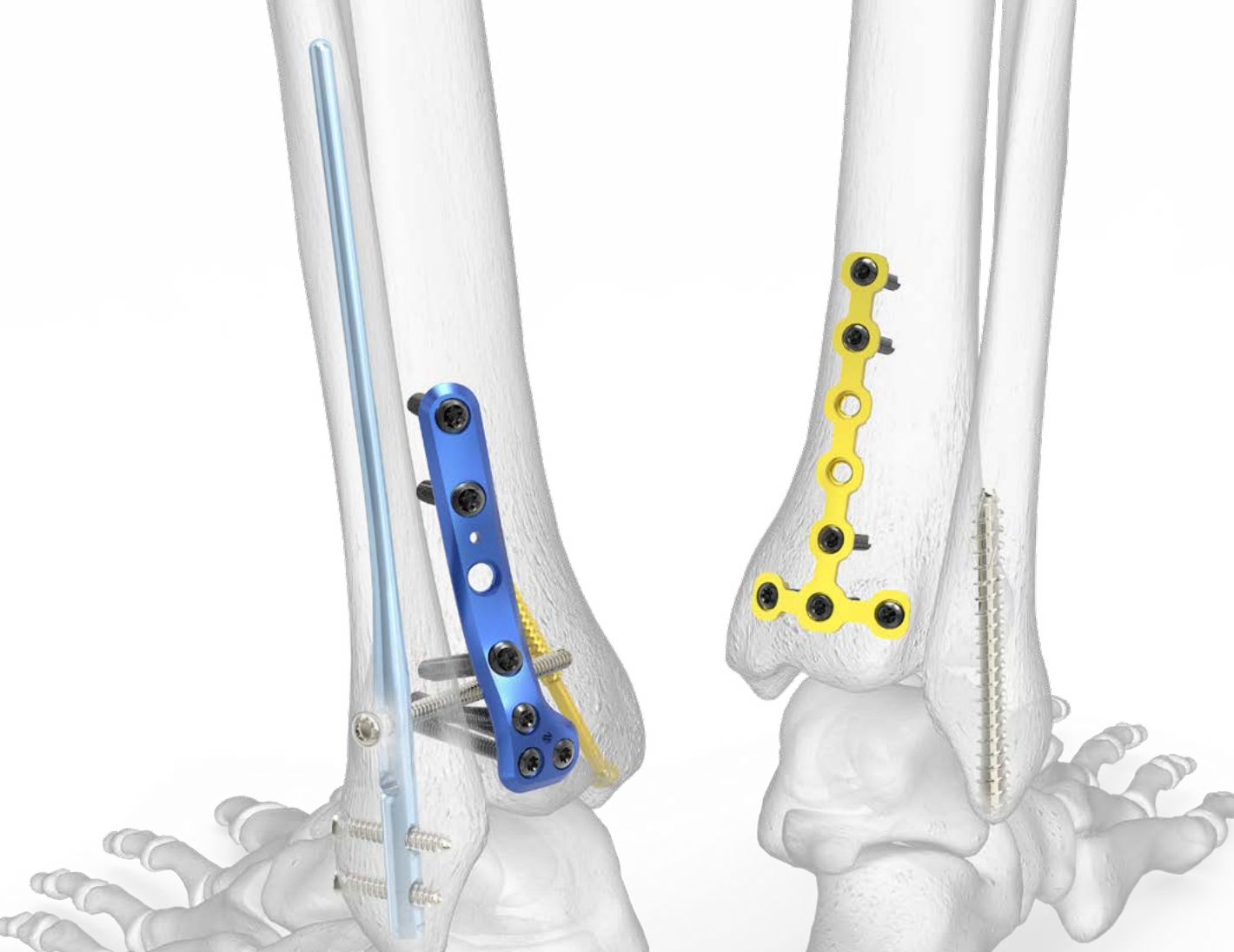
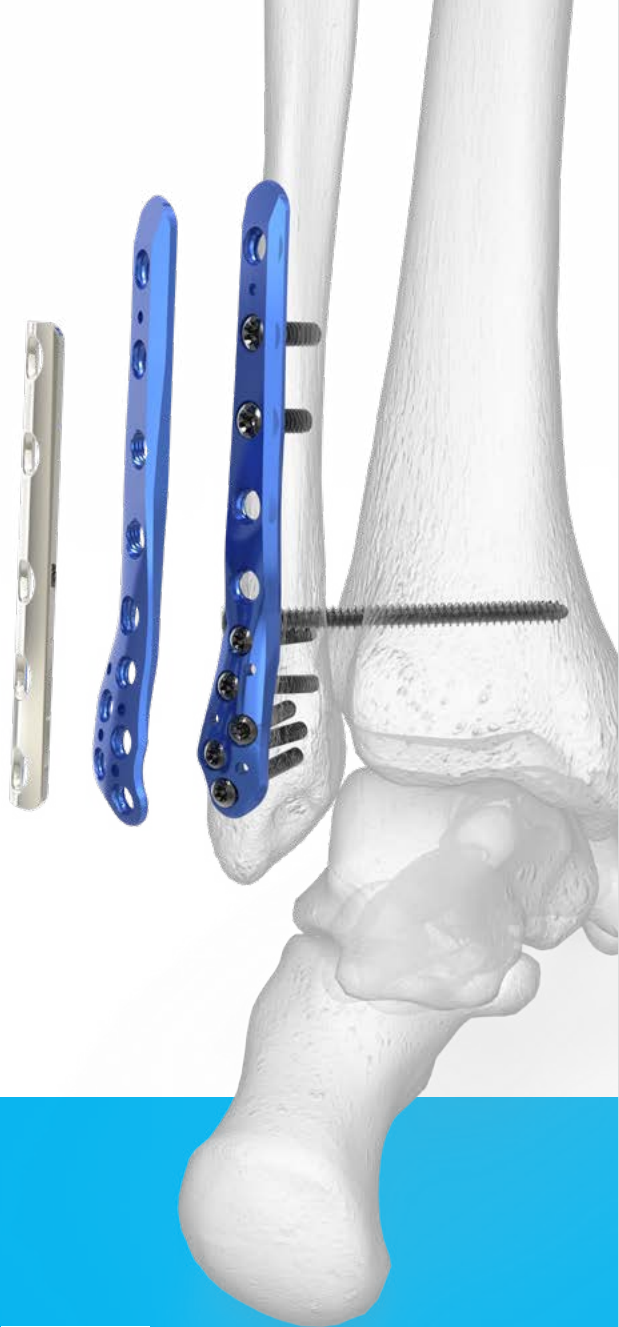Trimalleolar Fracture Solutions





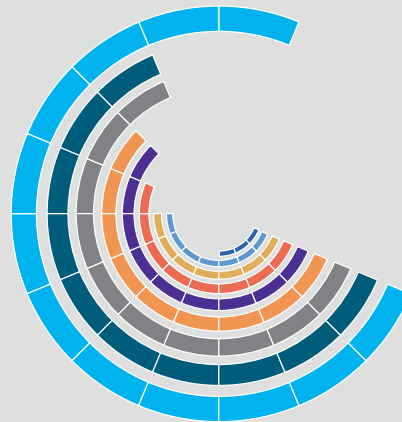
Acumed Has the Most Complete Selection of
Trimalleolar Fracture Treatment Options on
the Market*




Lower Extremity Fixation: Acumed vs the Competition*

See below for a visual guide to how our offerings stack up against ten of our competitors.

Ankle



Screws



For more information:
go.acumed.net/TriMal
 888.627.9957

Lateral Malleolus Fixation Solutions

Thin Distal Taper

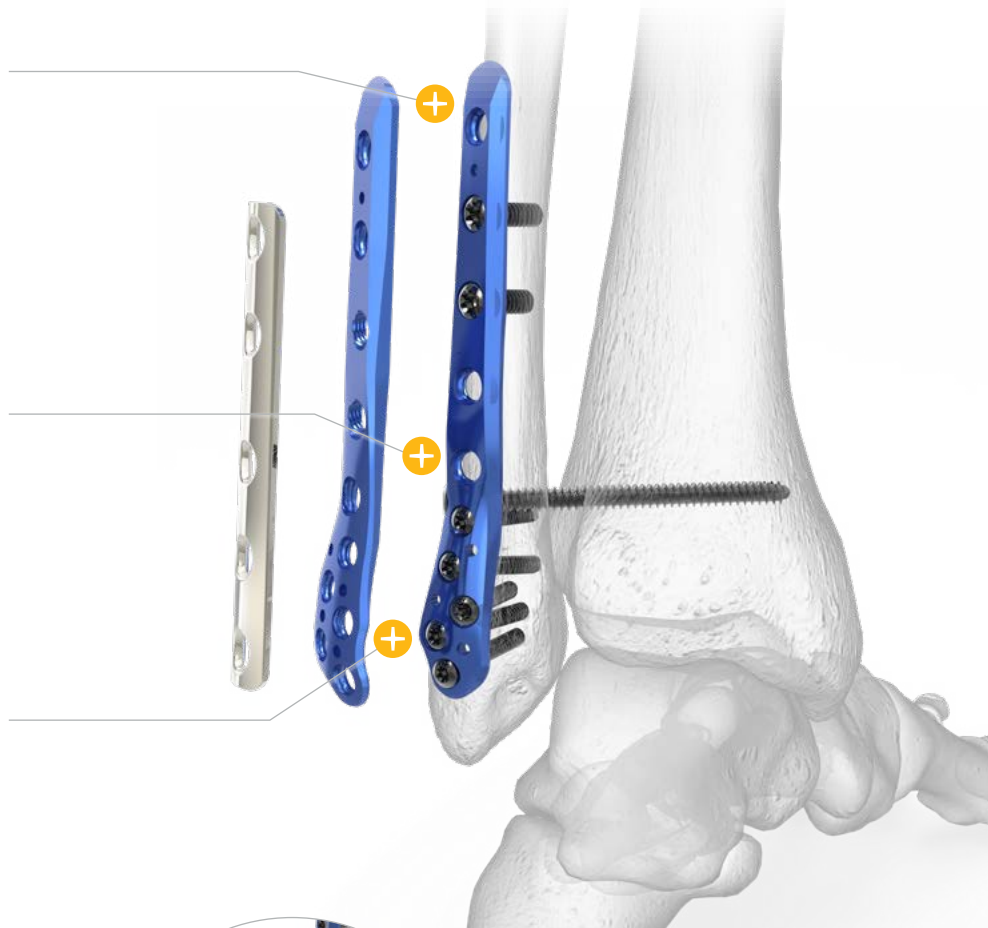
Designed to minimize soft tissue irritation, Lateral and Posterolateral Fibula Plates measure 1.5 mm at the distal end.

Syndesmotic Fixation Features

Features in the Lateral and Posterolateral Fibula Plates are designed for targeted syndesmotic screw fixation.

Distal Screw Cluster

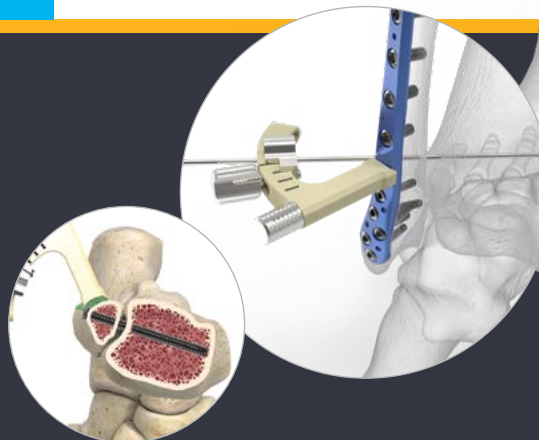
2.7 mm screw cluster allows for the capture of distal comminution.

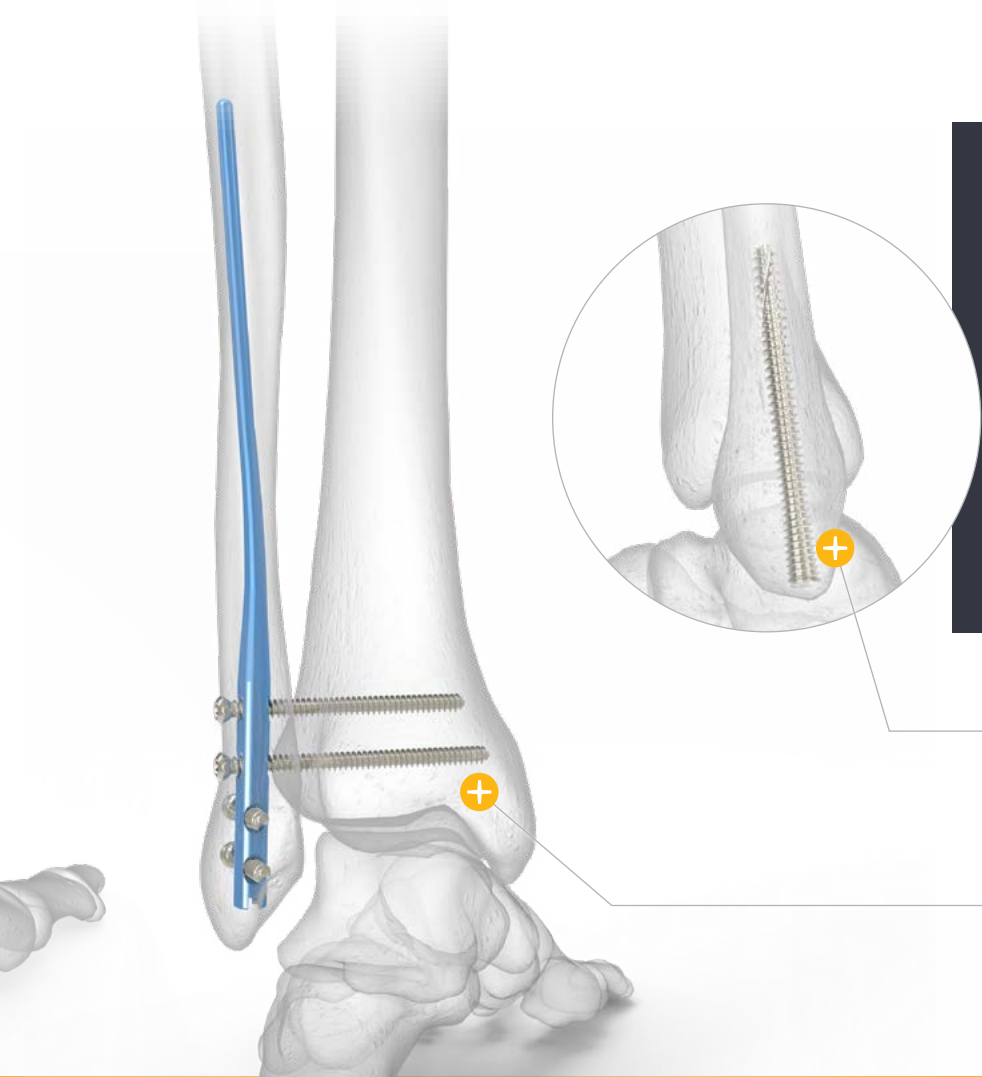


Specialty Instrumentation

Syndesmosis Targeting Guide

Unique to Acumed, the guide attaches to the Posterolateral Fibula Plate and is designed to target the desired angle for syndesmotic screw fixation.





Lateral Malleolus Solutions

- ▶ Ankle Plating System 3
 - ▶ Lateral Fibula Plate
 - ▶ Posterolateral Fibula Plate
 - ▶ Hook Plate
 - ▶ Locking Peg Hook Plate
 - ▶ 4.0 mm Cannulated Screws
- ▶ Fibula Rod System
- ▶ Small Fragment Base Set
 - ▶ One-Third Tubular Plates
 - ▶ 2.7 mm Fragment Plates
- ▶ Acutrak 2® Headless Compression Screw System

Acutrak® Technology

A clinical study showed the fully threaded, continuously variable Acutrak thread pitch provides compression and aids in rotational stability of the fibula.¹

Percutaneous Fixation


An alternative to ORIF, the Fibula Rod is inserted through small incisions while also accommodating syndesmotic screw fixation.

An Industry First



Acutrak Headless Compression Screw System

Released in 1994, the original Acutrak Headless Compression Screw was the first fully threaded headless compression screw on the market with continuously variable thread pitch.



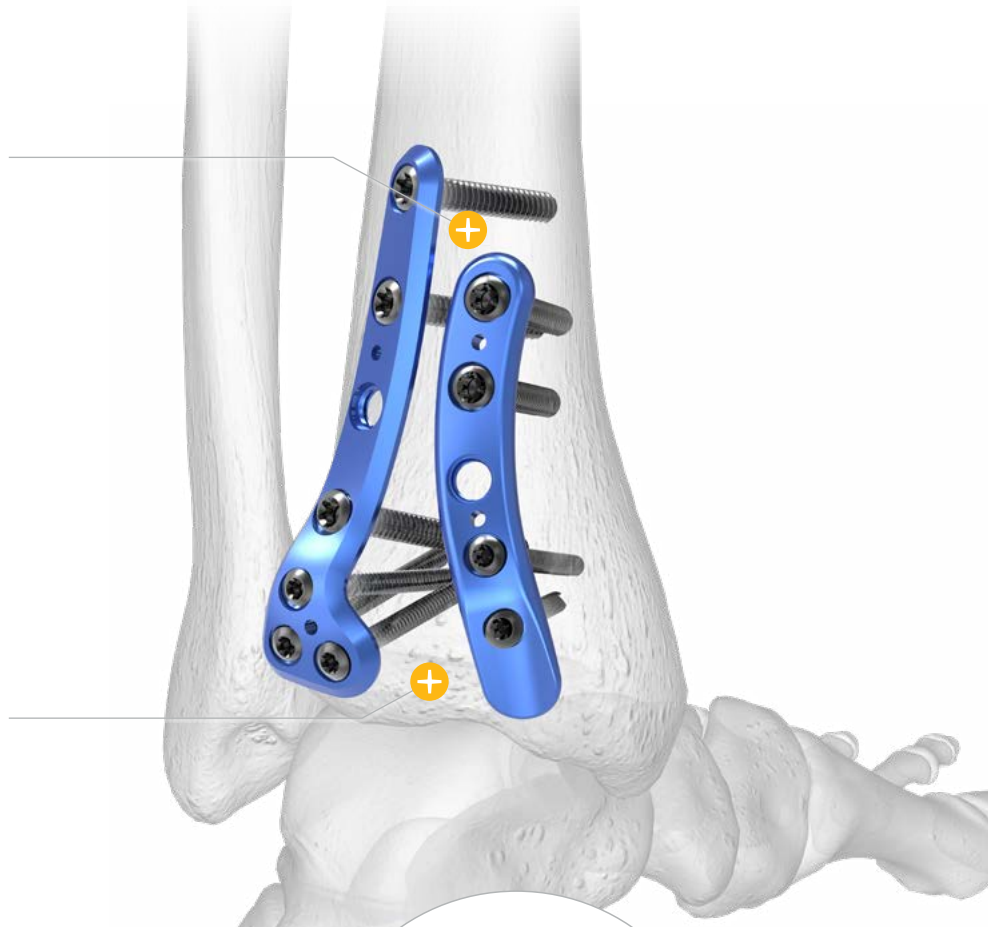Posterior Malleolus Fixation Solutions

Thin Distal Plate End

Posterolateral and Posteromedial Distal Tibia plates taper distally to minimize soft tissue irritation.

15° Screw Trajectories

Distal 2.7 mm screws are angled 15° superiorly to avoid the joint space.

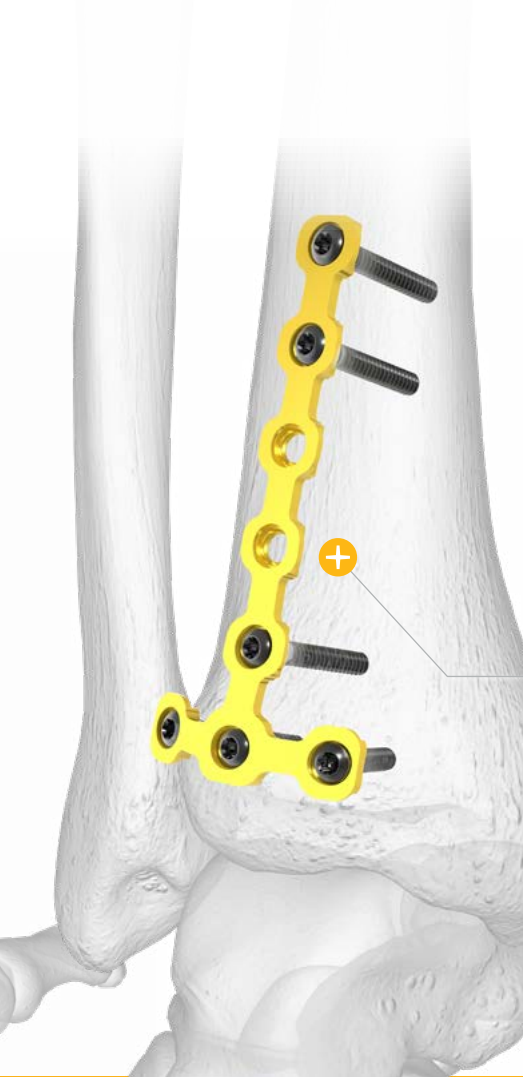


Specialty Instrumentation

2.7 Fragment Plate Cutter and Plate Benders

2.7 mm Fragment Plates can be bent *in situ* or *ex situ* to accommodate patient anatomy and fracture pattern.





Posterior Malleolus Solutions

- ▶ Ankle Plating System 3
 - ▶ Posterolateral Distal Tibia Plate
 - ▶ Posteromedial Distal Tibia Plate
 - ▶ 4.0 mm Cannulated Screws
- ▶ Small Fragment Base Set
 - ▶ One-Third Tubular Plates
 - ▶ 2.7 mm Fragment Plates
- ▶ Acutrak 2® Headless Compression Screw System

2.7 mm Fragment Plates

A cost-effective fracture solution.

Acutrak 2 Headless Compression Screw System

The Acutrak screw's continuously variable thread pitch design allows a fracture or osteotomy site to lie almost anywhere along the length of the screw.

An Industry First



Ankle Plating System 3

The industry's first fragment-specific Posterior Distal Tibia Plates launched in 2015.

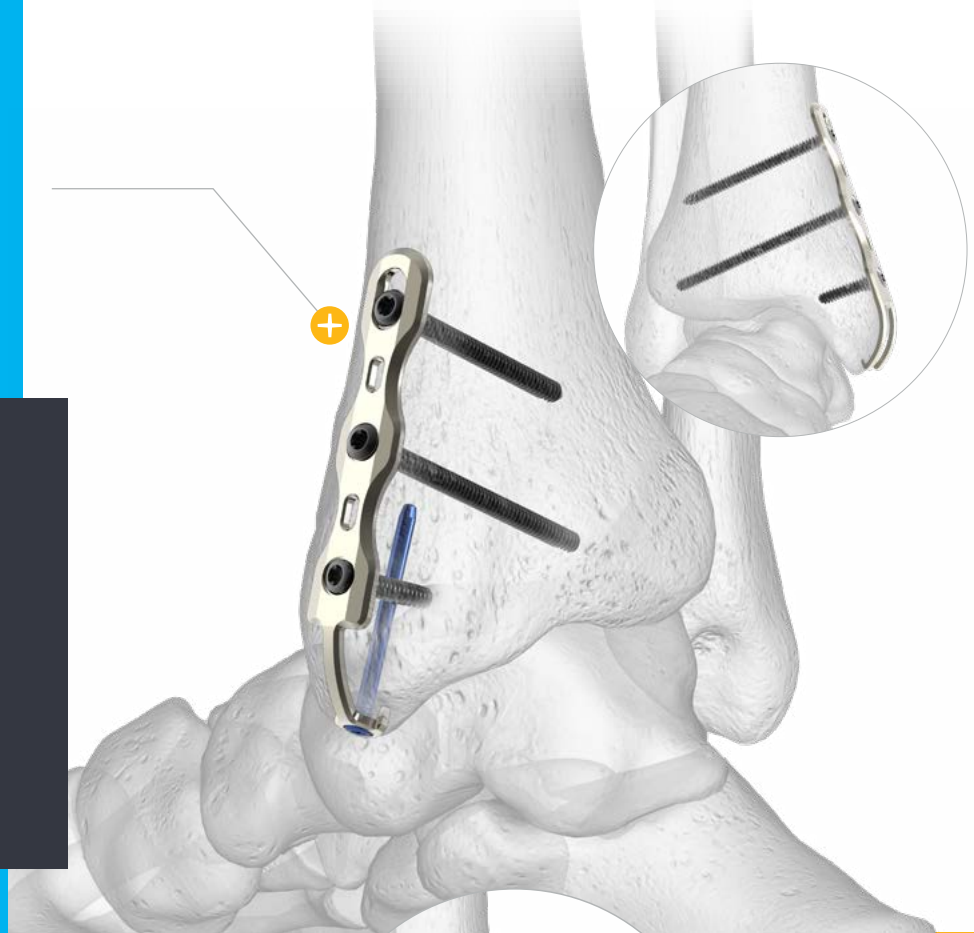
Medial Malleolus Fixation Solutions

Two Hook Plate Options

Traditional Hook Plates are available for small avulsion fragments, while the Locking Peg Hook Plate is available for stabilizing larger avulsion fragments.

Medial Malleolus Fixation Solutions

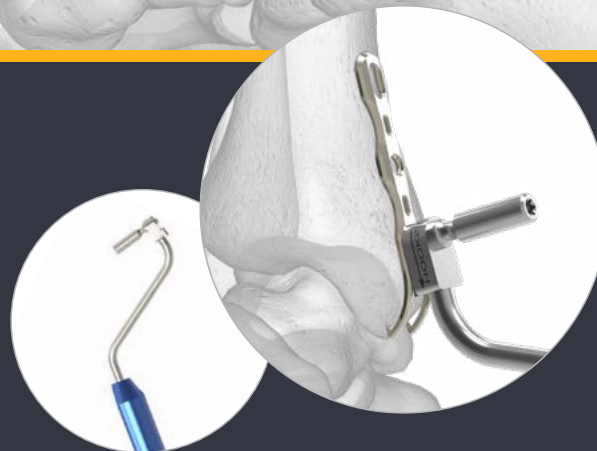- ▶ Ankle Plating System 3
 - ▶ Medial Anti-Glide Plate
 - ▶ Hook Plate
 - ▶ Locking Peg Hook Plate
 - ▶ 4.0 mm Cannulated Screws
- ▶ Small Fragment Base Set
 - ▶ One-Third Tubular Plates
 - ▶ 2.7 mm Fragment Plates
- ▶ Acutrak 2® Headless Compression Screw System

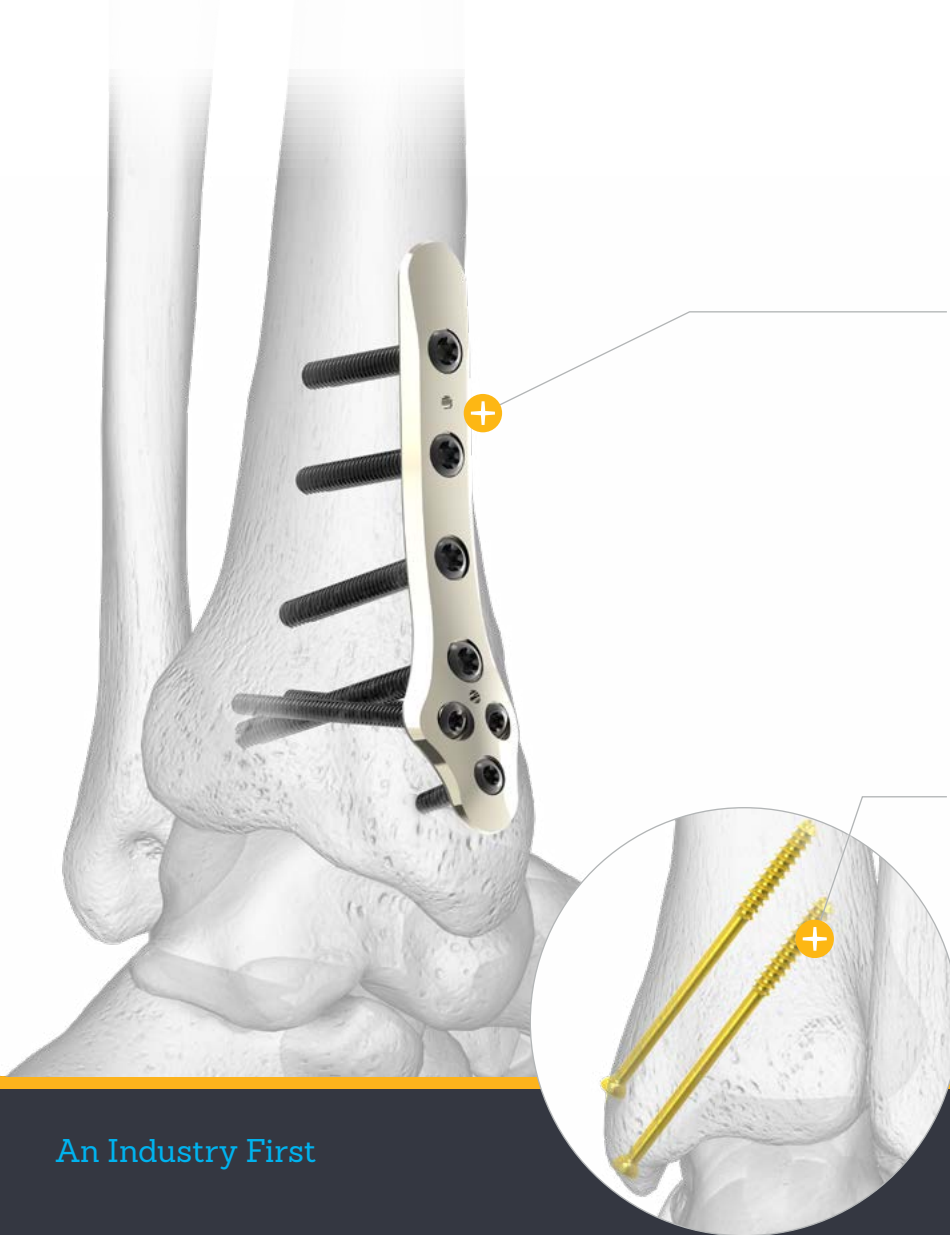

Specialty Instrumentation

Hook Plate Reduction Handle

Attaches to the Hook Plates and Locking Peg Hook Plates to aid in reduction and control plate placement. The attached cannulated bolt threads into the most distal plate hole.





Medial Anti-Glide Plate

Designed to buttress vertical shear fractures from proximal migration.

4.0 mm Cannulated Screws

May be used percutaneously to provide stability in a noncomplex medial malleolus fracture fixation.

An Industry First



Ankle Plating System 3

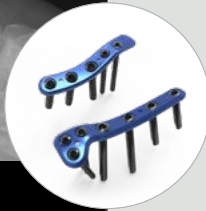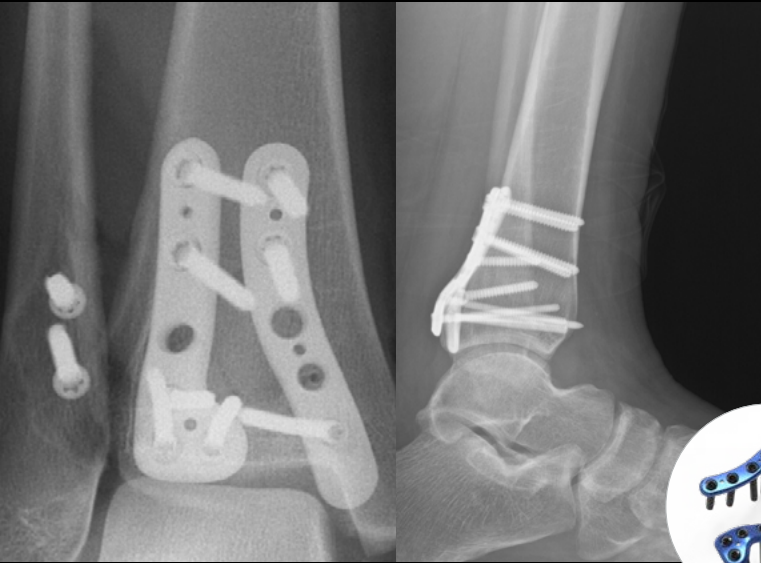
The Hook Plate Reduction handle allows for controlled fixation and reduction.

Case Studies

Dual Plating for Posterior Pilon Fractures

Jeffrey D. Seybold, MD


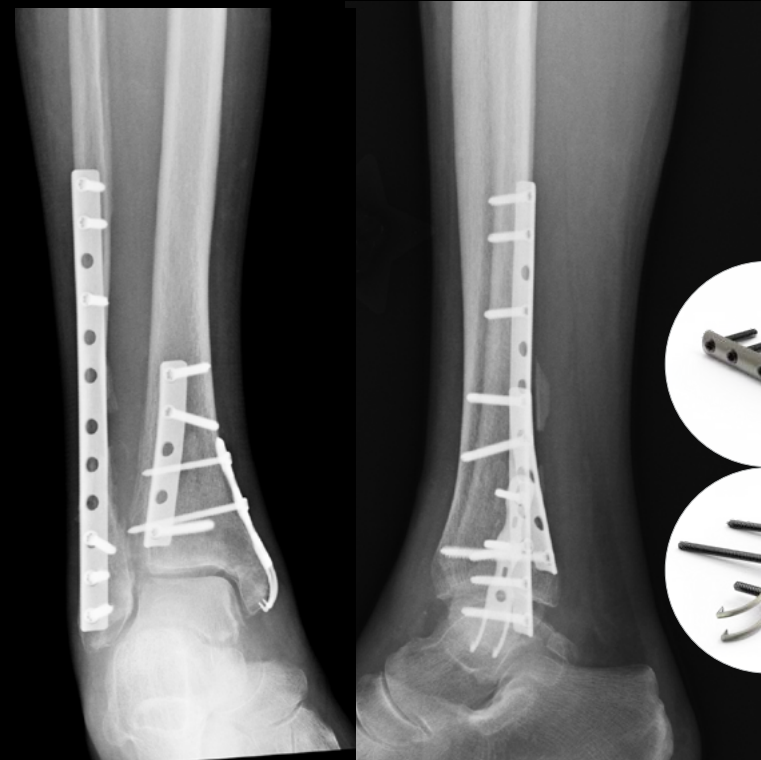
A 38-year-old female who sustained a left ankle fracture with significant posterior malleolar fracture fragments was treated successfully with the Acumed Ankle Plating System 3.



Trimalleolar Ankle Fracture Dislocation Treatment Using Plate and Screw Fixation

Kent Ellington, MD

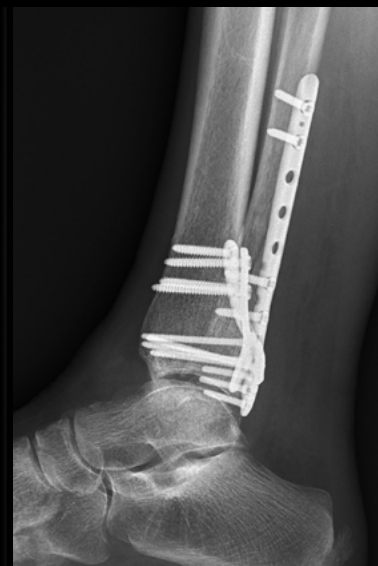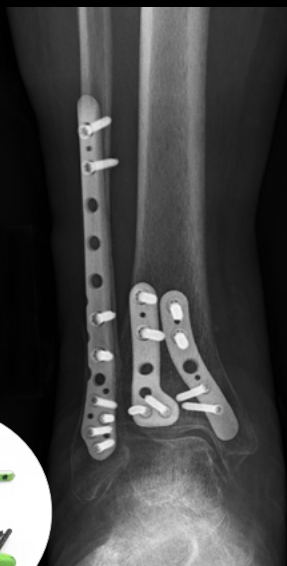A 70-year-old female with a closed trimalleolar fracture dislocation was treated with the Acumed Ankle Plating System 3 and Small Fragment Base Set.



Providing Stability to the Syndesmosis by Plating the Posterior Malleolus

Jeffrey D. Seybold, MD

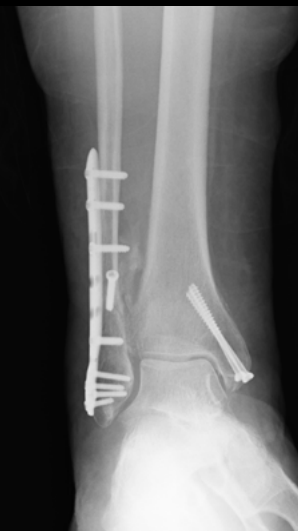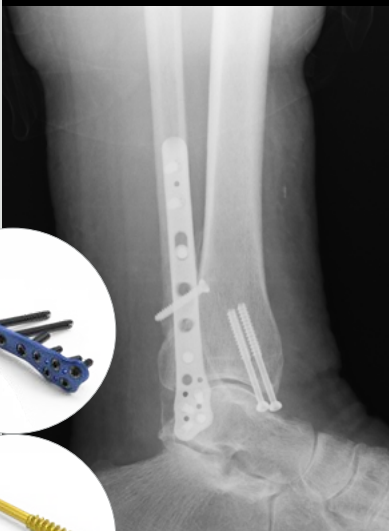
A 69-year-old female who sustained an ankle dislocation with associated distal fibula, posterior pilon, and deltoid avulsion fractures was treated successfully with the Acumed Ankle Plating System 3.



Closed Bimalleolar Ankle Fracture Treatment Using Anatomic Rigid Fixation

Kent Ellington, MD

A 53-year-old male with a closed bimalleolar fracture was treated with the Acumed Ankle Plating System 3 and Small Fragment Base Set.

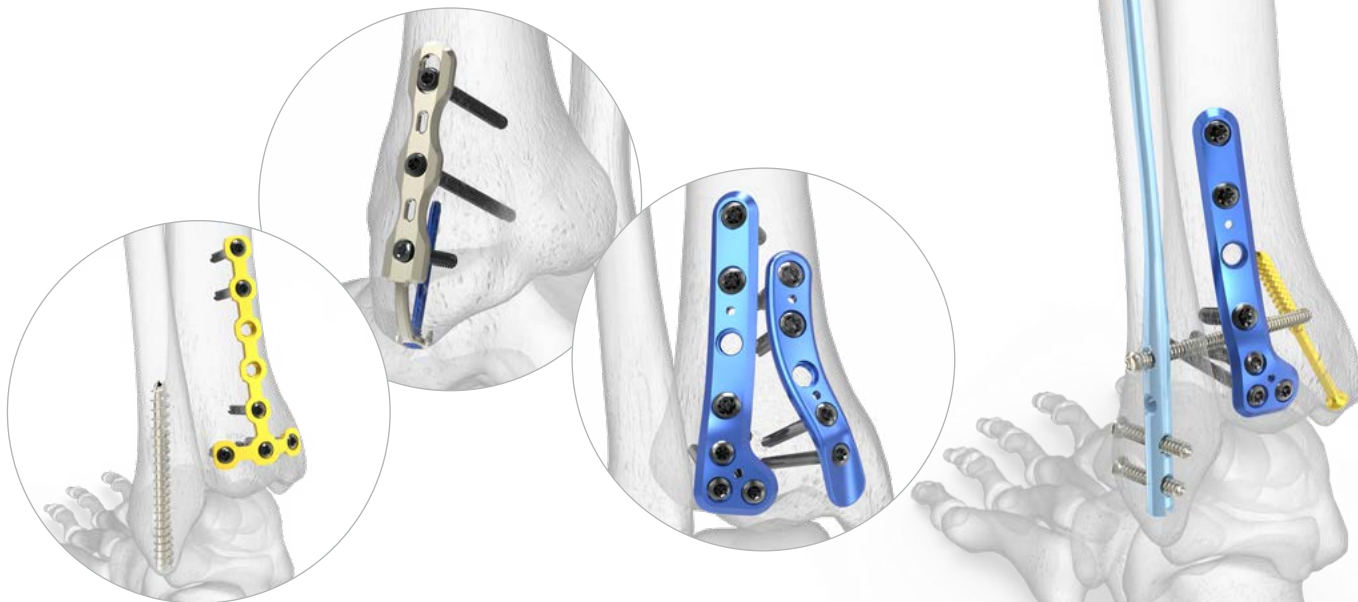


Acumed has the most complete selection of lower extremity fixation and specialty plates on the market.*

Lower Extremity Fixation: Acumed vs the Competition

Screws

- ✔ Product in Portfolio
- ✘ Product Not in Portfolio
- ✔ Partial Offering



		Acumed	DePuy Synthes	Stryker	Smith & Nephew	Zimmer Biomet	Wright Medical	Arthrex	Medartis	Paragon 28	TriMed
Screws	Headless	Continuous Compression	✘	✘	✘	✘	✘	✘	✘	✘	✘
		Differential Pitch	✘	✔	✔	✔	✔	✔	✔	✔	✔
	Headed	Partial Thread	✔	✔	✔	✔	✔	✔	✘	✔	✘
		Full Thread	✔	✔	✔	✔	✔	✔	✘	✘	✔

Ankle

✔ Product in Portfolio

✘ Product Not in Portfolio

✔ Partial Offering

		Acumed	DePuy Synthes	Stryker	Smith & Nephew	Zimmer Biomet	Wright Medical	Arthrex	Medartis	Paragon 28	TriMed
Distal Fibula	Fibula Nail	✔	✘	✘	✘	✘	✘	✔	✘	✘	✘
	Lateral Fibula Plates	✔	✔	✔	✔	✔	✔	✔	✘	✔	✔
	Posterolateral Fibula Plates	✔	✔	✔	✔	✔	✘	✔	✘	✔	✘
	1/3 Tubular Plates	✔	✔	✔	✔	✔	✔	✔	✘	✔	✔
Distal Tibia	Hook Plate	✔	✘	✘	✘	✘	✔	✔	✘	✔	✔
	Locking Peg Hook Plate	✔	✘	✘	✘	✘	✘	✘	✘	✘	✘
	Posterolateral Tibia Plate	✔	✘	✘	✘	✘	✘	✘	✘	✔	✘
	Posteromedial Tibia Plate	✔	✘	✘	✘	✘	✘	✘	✘	✔	✘
	Medial Tibia Plate	✔	✔	✔	✔	✔	✔	✔	✘	✔	✘
	Anterior Tibia Plates	✔	✔	✘	✔	✘	✔	✔	✘	✘	✘
	Anterolateral Tibia Plates	✘	✔	✔	✔	✔	✘	✘	✘	✘	✘
	Anteromedial Tibia Plates	✘	✔	✘	✘	✘	✘	✘	✘	✘	✘
	Medial Anti-glide Plate	✔	✔	✘	✘	✘	✘	✘	✘	✘	✘
	Fragment Plates	✔	✔	✔	✔	✔	✔	✔	✘	✔	✘
	Ankle Fusion Plate	✘	✘	✘	✔	✘	✔	✔	✘	✔	✘
	External Fixation	✘	✔	✔	✔	✔	✔	✔	✘	✘	✘

Ankle Plating System 3 Key Publications

Stability of the Syndesmosis After Posterior Malleolar Fracture Fixation

Publication Excerpt

“Our data demonstrates that the rate of syndesmotic instability was reduced in trimalleolar and trimalleolar equivalent fractures when prone positioning and direct fixation of the posterior malleolus were first performed.”



Reference

Miller MA, McDonald TC, Graves ML, et al. Stability of the syndesmosis after posterior malleolar fracture fixation. *Foot Ankle Int.* 2018; 39(1):99-104.

“A to P” Screw vs Posterolateral Plate for Posterior Malleolus Fixation in Trimalleolar Ankle Fractures

Publication Excerpt

“Patients with trimalleolar ankle fractures in whom the posterior malleolus was treated with posterolateral buttress plating had superior clinical outcomes at follow-up compared with those treated with AP screws.”



Reference

O'Connor T, Mueller B, Ly TV, et al. “A to P” screw versus posterolateral plate for posterior malleolus fixation in trimalleolar ankle fractures. *J Orthop Trauma.* 2015; 29(4):e151-6.

Pathoanatomy of Posterior Malleolar Fractures of the Ankle

Publication Excerpt

“[P]osterior malleolar fractures can be classified into three types, and fracture lines of posterior malleolar fractures vary greatly. A large fragment extending to the medial malleolus was present in almost 20% of the observed posterior malleolar fractures and is thus not necessarily rare. Some of these fragments involved the entire medial malleolus. Assessing the size of posterior malleolar fragments radiographically may be impossible because of the irregularity of the fracture line.”



Reference

Haraguchi N, Haruyama H, Toga H, Kato F. et al. Pathoanatomy of posterior malleolar fractures of the ankle. *J Bone Joint Surg Am.* 2006;88:1085-92.

Fibula Rod System Key Publications

The Fibula Nail for Treatment of Ankle Fractures in Elderly and High Risk Patients

Publication Excerpt

“The fibula nail provides an alternative to standard plate fixation that uses a minimal approach and, therefore, decreases the incidence of wound infection and the need for further surgery to remove prominent metalwork while providing stable fixation.”

View Original Article



Reference

Appleton P, McQueen M, Court-Brown C. The fibula nail for treatment of ankle fractures in elderly and high risk patients. *Tech Foot Ankle Surg.* 2006;5(3):204-208.

The Treatment of Unstable Fractures of the Ankle Using the Acumed Fibular Nail: Development of a Technique

Publication Excerpt

“Nailing of the fibula using our current technique gives good radiological and functional outcomes with minimal complications, and should be considered in the management of patients with an unstable ankle fracture.”

View Original Article



Reference

Bugler KE, Watson CD, Hardie AR, et al. The treatment of unstable fractures of the ankle using the Acumed fibular nail: development of a technique. *Bone Joint J.* 2012;94-B(8):1107-1112.

Intramedullary Fixation Versus Plate Fixation of Distal Fibular Fractures: A Systematic Review and Meta-Analysis of Randomized Controlled Trials and Observational Studies

Publication Excerpt

“This systematic review and meta-analysis shows that in a patient population of relatively high age, IMF (intermedullary fixation) of distal fibular fractures results in fewer wound-related complications, implant removals, and nonunions. In addition, subdivision of wound-related complications showed fewer wound healing disorders and superficial wound infections.” (compared to plate fixation)

View Original Article



Reference

Tas D, Smeeing D, Emmink B, Govaert G, Hietbrink F, Leenen L, et al. Intramedullary fixation versus plate fixation of distal fibular fractures: a systematic review and meta-analysis of randomized controlled trials and observational studies. *J Foot Ankle Surg.* 2019;58:119-126.



Acumed Headquarters
5885 NE Cornelius Pass Road
Hillsboro, OR 97124
Office: +1.888.627.9957
Office: +1.503.627.9957
Fax: +1.503.520.9618
www.acumed.net

FNA00-06-B | Effective: 2020/08 | © 2020 Acumed® LLC

***Competitive data on file with Acumed. GEN00-30-B; 2020.**

References

1. Chen SH, Huang CR, Hsu TL, Lee YS. Lateral fixation of AO type-B2 ankle fractures: the Acutrak Plus compression screw technique. *Int Orthop*. 2010;34(6):903-907

These materials contain information about products that may or may not be available in any particular country or may be available under different trademarks in different countries. The products may be approved or cleared by governmental regulatory organizations for sale or use with different indications or restrictions in different countries. Products may not be approved for use in all countries. Nothing contained in these materials should be construed as a promotion or solicitation for any product or for the use of any product in a particular way that is not authorized under the laws and regulations of the country where the reader is located. Nothing in these materials should be construed as a representation or warranty as to the efficacy or quality of any product, nor the appropriateness of any product to treat any specific condition. Physicians may direct questions about the availability and use of the products described in these materials to their authorized Acumed distributor. Specific questions patients may have about the use of the products described in these materials or the appropriateness for their own conditions should be directed to their own physician.

Acumed® and Acutrak 2® are registered trademarks of Acumed LLC