

## Case example and role of the Acumed Fibula Rod

### Patient:

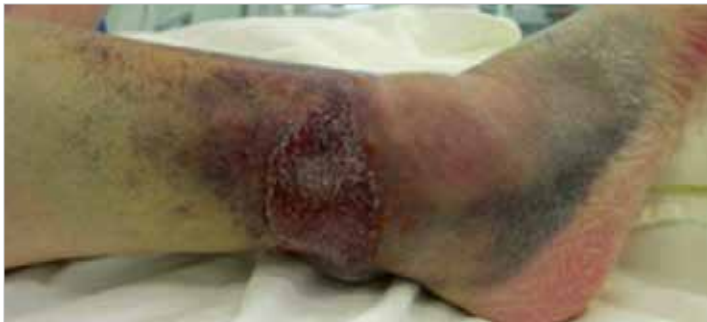76 year old female, retired orthopaedic nurse.

### Mechanism of Injury:

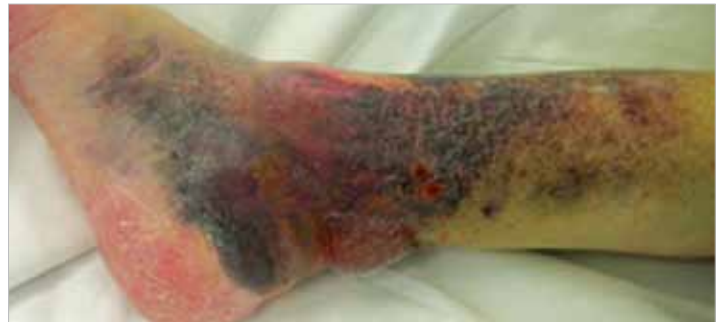Stepped off of a curb, twisting her right ankle.

### Patient Background:

No significant past medical history, including no diabetic issues nor cardiovascular issues.



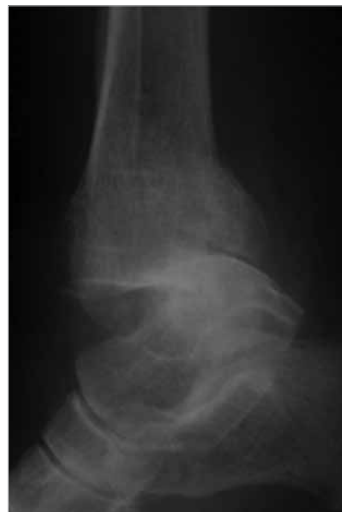Intraoperative photo lateral



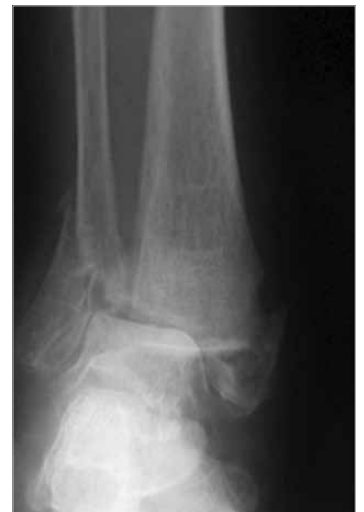Intraoperative photo medial

### Solution:

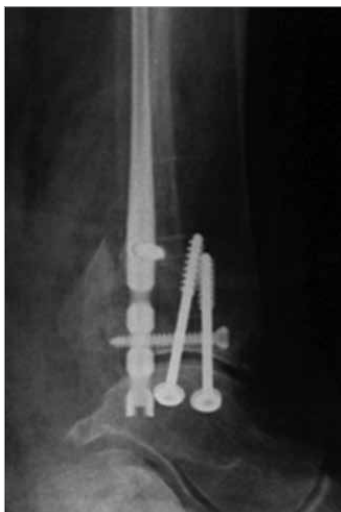
Surgeon decided to use Acumed's Fibula Rod System due to swelling and blistering. Open reduction of the lateral malleolus could have resulted in wound complications. The medial side was also fixed using a minimally invasive approach (two lag screws).



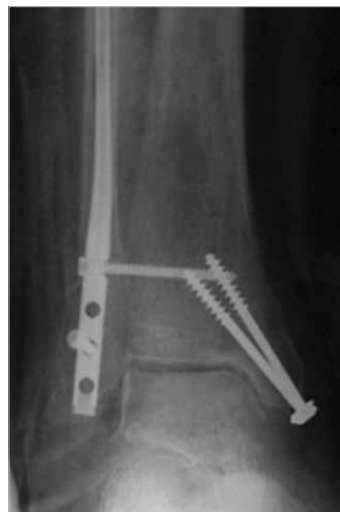Pre-op x-ray M/L



Pre-op x-ray A/P



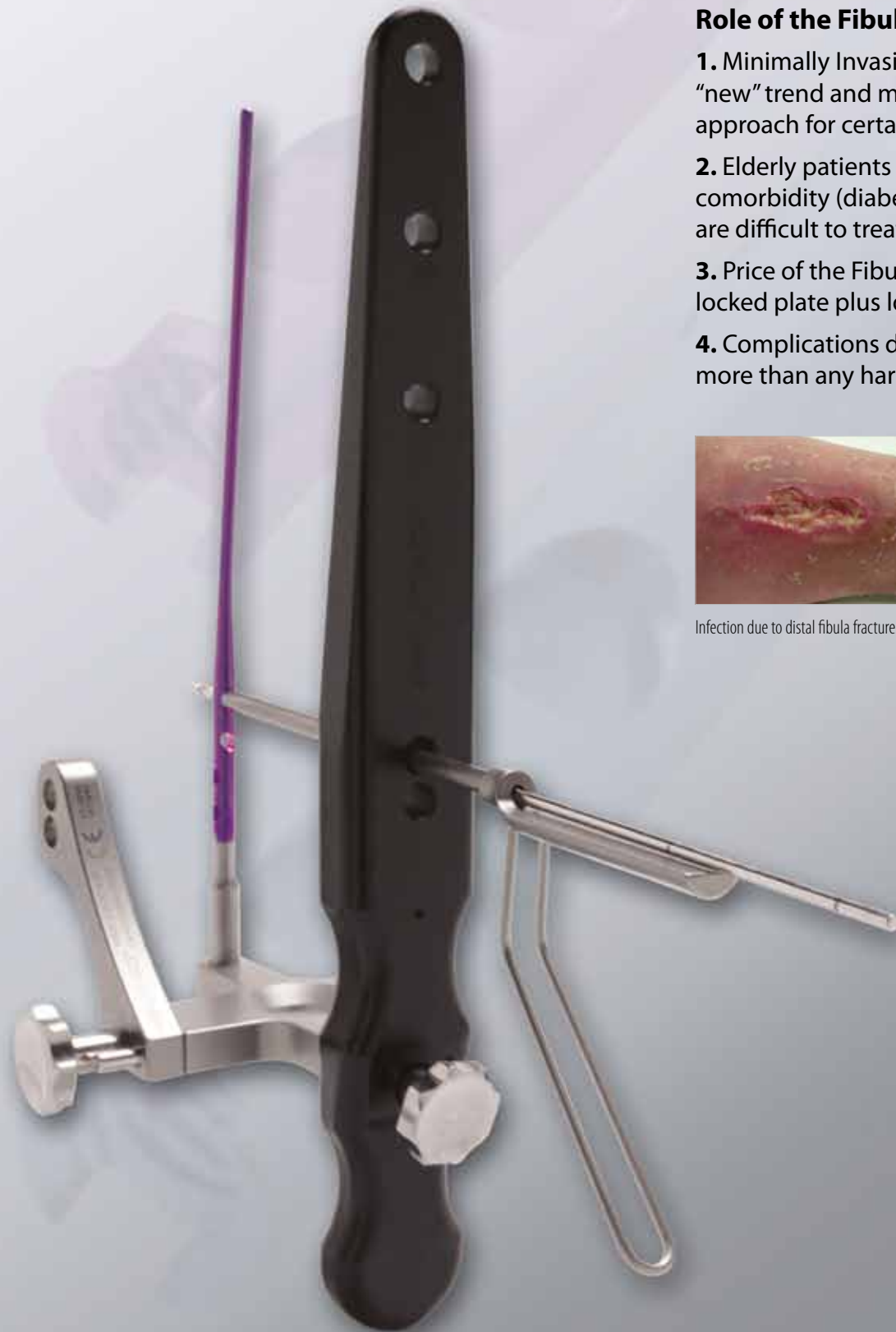Post-op x-ray M/L



Post-op x-ray A/P

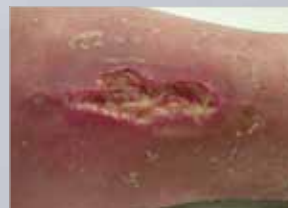### Case conclusions

- Ankle injuries in the elderly can be difficult to treat
- Most studies have shown a very high complication rate
- The Acumed Fibula Rod provides an alternative method to plate fixation

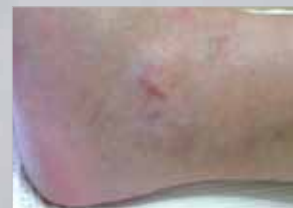

## Role of the Fibula Rod:

1. Minimally Invasive Surgery (MIS) is a “new” trend and may be the preferred approach for certain patients.
2. Elderly patients and those with comorbidity (diabetes and vascular issues) are difficult to treat.
3. Price of the Fibula Rod is comparable to locked plate plus locking screws.
4. Complications due to infection may cost more than any hardware.



Infection due to distal fibula fracture.



Minimally invasive approach using Acumed's Fibula Rod System reduces noticeable wounds during healing.